

# Advancing Keloid Treatment: A Novel Multimodal Approach to Ear Keloids

MICHAEL E. JONES, MD,\* JENNIFER McLANE, FNP,\* RACHAEL ADENEGAN, FNP-C,\* JOANNE LEE, PA-BC,\* AND CHRISTINE A. GANZER, PMHNP, PhD†

---

**BACKGROUND/OBJECTIVE** Management of keloids of the pinna, in particular, those located in the helix and antihelix and lobule that occur as complications of ear piercing.

**MATERIALS AND METHODS** Retrospective analysis of 49 patients treated with extralesional surgical excision of keloids localized to the ear followed by the application of autologous platelet-rich plasma (PRP) to wound site and postoperative in-office superficial radiation therapy (SRT). Radiation protocol consisted of 1 to 3 fractions, with cumulative dosage ranging from 1,300 to 1,800 cGy. Average follow-up was 24 months to assess for evidence of recurrence and adverse side effects.

**RESULTS** Fifty ear keloids were treated with this method, age from 15 to 66 (mean = 32, SD = 16) of which 14 were male and 35 female. Almost 30% ( $n = 14$ ) of patients acknowledged the source of injury that led to the development of the keloid was ear piercing. Treatment protocol achieved a 94% success rate with 3 patients who reported recurrence.

**CONCLUSION** Surgical excision combined with intraoperative PRP, adjuvant postoperative in-office SRT achieved a 94% nonrecurrence rate on follow-up over a 2-year period. Outcomes provide preliminary, albeit, strong evidence to support this multimodal method as a viable alternative in the management of keloids localized to the ear.

*The authors have indicated no significant interest with commercial supporters.*

---

Keloids are benign fibrous proliferative tumors that can occur spontaneously or as the result of minor trauma or injury to the skin. Classically, they appear as a firm, bosselated, and often shiny mass that may be accompanied by hyperpigmentation.<sup>1</sup> The formation of keloids typically results in the invasion of adjacent normal tissue well beyond the margins of the original scar. The tumors have been known to form in all races; however, they are seen more frequently among persons of color—including those of African, Latino, and Asian descent with the highest incidence in the third and fourth decades of life.<sup>2,3</sup> Keloids can occur on any part of the body with common sites being the anterior chest, upper arm, shoulder, and face. These often unsightly growths have been known to cause considerable pruritus and follicular entrapment along with co-occurring chronic infections that result

in purulent discharge resulting in both physical disfigurement and emotional distress.<sup>4</sup>

In recent years, multiple piercings of the ear has gained popularity and of particular concern is that keloids have been known to develop secondary to piercings, and therefore, they can involve both the upper third of the pinna and the earlobe. Keloids of the ear have been known to grow aggressively enveloping surrounding tissue.

The exact etiology in the development of these lesions is unknown, and there are few successful treatments that result in full resolution of these often painful lesions. Historically, surgical excision has been the basis for treatment. However in part because of unsuccessful therapy, surgeons have opted to explore

\*Lexington Plastic Surgeons, New York, New York; †Hunter-Bellevue School of Nursing, Hunter College, New York, New York

© 2017 by the American Society for Dermatologic Surgery, Inc. Published by Wolters Kluwer Health, Inc. All rights reserved.  
ISSN: 1076-0512 • Dermatol Surg 2017;0:1–6 • DOI: 10.1097/DSS.0000000000001145

the use of multimodal treatments including adjuvant use of corticosteroid injections and topically controlled pressure therapy.<sup>5,6</sup> Corticosteroids exert an anti-inflammatory effect while reducing collagen, the synthesis of glycosaminoglycan, and limit the production of fibroblasts. These treatments have targeted ways to accelerate the healing process which occurs before epithelialization of the wound; however, their exact mechanisms remain poorly understood, and the use of a single modality to treat keloids has had variable results.<sup>7</sup>

Histologically, keloid tissue has been shown to contain an overabundance of Type-I and Type-III dermal collagen and multiple fibroblast proteins suggesting the dysregulation of cellular wound healing.<sup>8</sup> Physiologically, wound healing in adult tissue can be categorized into 3 stages: inflammation, proliferation, and remodeling.<sup>2</sup> At the onset of wounding, there is an activation of complement and clotting cascade that begins the framework for tissue repair. It is at this time that platelet degranulation initiates a host of factors such as epidermal growth factor and transforming growth factor  $\beta$  which in turn acts to recruit important agents such as neutrophils, macrophages, mast cells, epithelial cells, and fibroblasts all that contribute to the healing process. After 48 to 72 hours, the second stage of proliferation begins that will last 3 to 6 weeks.<sup>9</sup> The extracellular matrix of granulation tissue is composed of a network of Type-III collagen, which is later replaced with a stronger long-stranded Type-I collagen. Wound healing in both soft and hard tissue is modulated by growth factors that are released and activated by platelets. A novel therapy that has been gaining popularity in the treatment of wounds is platelet releasate or platelet-rich plasma (PRP), the portion of plasma fraction of autologous blood that has a high concentration of platelets, clotting, and growth factors.<sup>10</sup> In recent years, PRP has been used to treat soft tissue ulcerations along with adjuvant therapy in periodontal, maxillofacial, orthopedic, and trauma surgery.<sup>11-14</sup> These applications have been shown to aid in healing through the local activation of several important platelet-derived growth factors, such as vascular endothelial growth factor, osteocalcin, osteonectin, fibrinogen, and thrombospondin-1.<sup>15,16</sup> The mechanism of action of these factors is to attract

undifferentiated cells found in the newly formed cellular matrix through the stimulation of mitosis. In addition to the promotion of cell division which aids in new capillary growth, PRP has been shown to have several positive benefits. An important research finding is that PRP may augment the suppression of proinflammatory cytokines combined with enhancing the mobilization of macrophages thereby contributing to the healing process.<sup>17</sup> Of particular importance is that several studies have shown that PRP has antimicrobial activity against several micro-organisms, including *Escherichia coli*, *Staphylococcus aureus*, and methicillin-resistant *Cryptococcus neoformans* all known to present in soft tissue and has been shown to lead to a more organized deposition of collagen during wound healing.<sup>18-20</sup>

Another important benefit of autologous PRP is that it is relatively simple to produce, and there is minimal effort needed to deliver the therapy at the time of treatment. Preparation of PRP aliquot involves obtaining a sample of the recipients' whole blood which is anticoagulated and then centrifuged to allow for the separation of plasma from packed red blood cells. Plasma is further centrifuged to remove PRP from platelet-poor plasma resulting in a jelly-like product enhancing its topical application. The novelty of PRP and its ease in preparation, application combined with intrinsic benefits, makes it ideal for the treatment of keloids. An important consideration in the use of PRP is cost, with multiple PRP centrifugation methods available to clinicians. Direct costs include disposable preparation kits that can vary from \$150 to \$400 depending on machine, with additional fees to cover PRP activators such as calcium chloride and bovine thrombin combined with indirect labor costs and overhead.

An important modality that has received limited application in the treatment of keloids is radiotherapy. Historically, radiation has been used for decades diagnostically and clinically in a host of medical conditions but primarily among malignant cancers. Recent advances in nuclear physics together with computer technology have led to the development of significant innovations allowing for more precise targeting of tissue. Because of these developments,

medicine has experienced a recent resurgence in the use of in-office superficial radiation therapy (SRT) in the treatment of nonmelanoma cancers such as basal and squamous cell by-passing the need for patients to seek treatment in a hospital setting, thereby creating a new opportunity to expand on these treatments for keloids. An important consideration in the use of SRT is that in comparison with high-energy machines used in radiation oncology, SRT is low energy, targets the skin sparing deeper structures, a factor ideal in the treatment of conditions that affect cutaneous maladies.<sup>21</sup> The cost of SRT treatments varies for each individual and is dependent on factors such as size of keloid and the extent of treatment necessary. In addition, it should be noted that few studies have investigated the long-term consequences of SRT, and therefore, all treatment options should be explored and risk versus benefit of selected modality fully disclosed.<sup>22</sup>

There are limited studies investigating the use of radiotherapy as an effective and safe adjuvant treatment of keloids. However, research to date supports radiotherapy as an effective method in the prevention of recurrence which is an often negative outcome of using surgery alone. In a recent study, researchers assessed the feasibility and efficacy of a radiation protocol using high-dose, single-fraction electron beam in a cohort of patients with treatment-resistant keloids.<sup>23</sup> All patients in this study ( $n = 12$ ) had previous, albeit unsuccessful, treatment for keloids with multimodal therapy including surgical excision and steroid injections, but not radiation. The mean post-procedure follow-up for patients was 20 months, with no reported recurrence of keloid. Despite a small sample size results positively support radiation as a safe and effective method that can limit the recurrence of intractable keloids. In a second long-term study, 91 keloids were treated surgically followed by radiation. Patients who were followed for 2 years and of those 51 (56.0%) showed complete remission providing further support for the use of radiation in the successful treatment of keloids.<sup>24</sup>

This study sought to investigate the use of a unique multimodal therapy in the treatment of auricular keloids. Therapy involved surgical excision followed

by the application of PRP to the surgical site along with the addition of adjuvant SRT. To further aid in the recurrence of keloids, surgical incisions were minimized using the advancement flap and rotation flap procedures. To the authors' knowledge, this combination of therapy in the treatment of keloids has not been previously reported by another research team specifically as a treatment for keloids confined to the ear.

## Methods

### *Study Population*

This study retrospectively reports the outcomes of a cohort of 49 subjects that sought management and treatment of keloids localized to the auricle. All subjects were examined and treated by 1 plastic surgeon, in a private practice setting, and all patients were counseled and signed standardized written informed medical consent before initiation of treatment. This retrospective study was conducted in accordance with "good clinical practice" and with the guidance of the ethical guidelines set forth by the Biomedical Research Alliance of New York Institutional Review Board.

### *Keloid Treatment Protocol*

A multiprong approach was developed and implemented by the lead author for the management of auricular keloids (e.g., earlobe) using the following outlined technique: extralesional surgical excision, subsequent application of PRP followed by an irradiation protocol started within 72 hours postprocedure. Before surgery, patients underwent a blood draw to obtain a sample necessary to prepare PRP using the Harvest SmartPrep System Platelet Concentrate (PC) Procedure Packs. This automated process entails a 14-minute centrifuge cycle to prepare the patients' autologous PRP. All keloids are assessed using the Kyoto Scar Assessment Scale, an instrument specifically designed for the evaluation of keloids that objectively measures redness, elevation, hardness together with subjective patient report of itching and pain.<sup>25</sup> Using local or intravenous anesthesia, keloids were then extirpated completely. The undermining technique is then used to minimize skin tension and

**TABLE 1. Patient Characteristics**

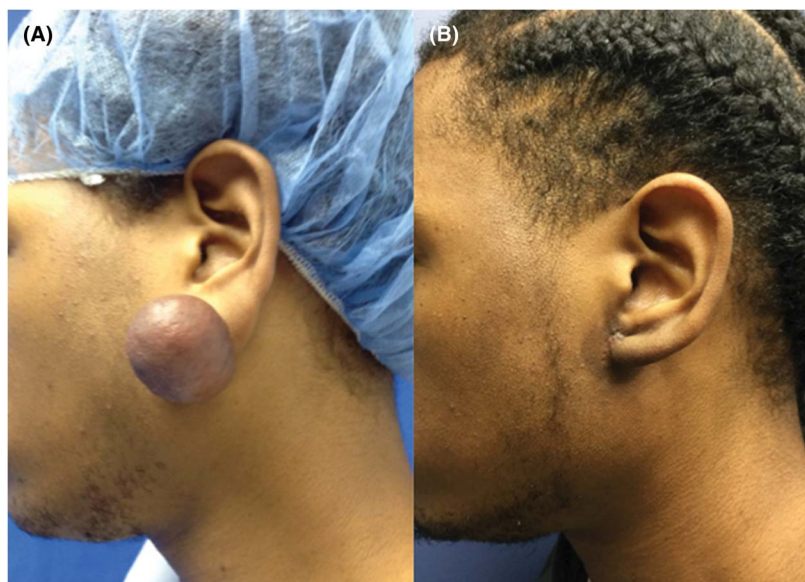<i>No. of Patients</i>	<i>n = 49 (50 Keloids)</i>
Age (range), yr	32 (15–66)
Sex, n (%)	
Male	14 (28.57)
Female	35 (71.43)
Family history of keloids, n (%)	
Yes	11 (22.45)
No	1 (2.04)
Unknown	37 (75.51)
Previous treatment of keloid, n (%)	
Yes	5 (10.20)
No	7 (14.29)
Unknown	37 (75.51)
Surgical excision	50 (100)
Superficial photon x-ray radiation (SRT)	50 (100)
Recurrence, n (%)	
Yes	3 (6)
No	48 (94)

promote closure of wound edges. Platelet-rich plasma is placed directly onto the wound bed and under skin flaps and then closed using the standardized subcuticular suture method to promote aesthetic appearance. Additional PRP is then applied directly to the closed incision site and allowed to dry. To provide added strength and protection, all wounds are also treated with Dermabond Advanced topical skin

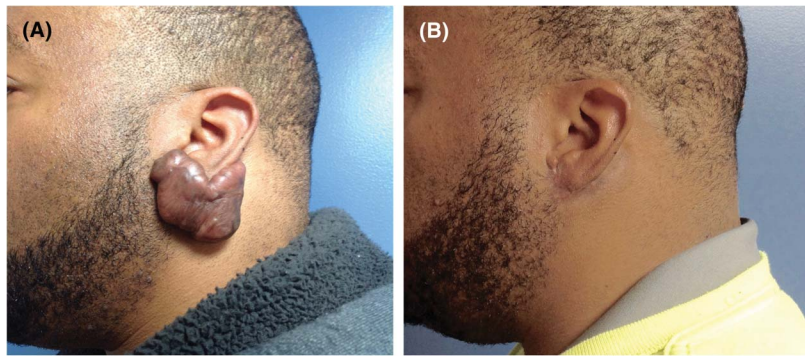adhesive followed by the linear application of Steri-Strips. The in-office radiation protocol involves the use of the Sensus Healthcare SRT-100 superficial photon x-ray radiation treatment system (SRT), a device approved by the Food & Drug Administration (FDA). The procedure entails irradiation of the wound post-surgically with SRT that penetrates up to 5 mm into the skin thereby limiting tissue damage. Custom-made lead shields are used to protect surrounding tissue and auricular keloids are treated with 70 K<sub>v</sub>, with cumulative radiation doses between 13 and 18 Gy. On completion of initial protocol, patients are instructed to follow-up 10 days, 1, 3, 6, 9, and 12 months post-surgically. Patients are also instructed to apply Keloid Care, a proprietary cream formulated specifically for the treatment of keloid scars that contains ingredients known to promote the healing process such as silicone, vitamin E and antioxidants, and 0.5% hydrocortisone twice daily for the first 3 months.

## Results

A total of 49 patients and 50 keloids were treated with the described protocol from November 2013 to November 2015 at the authors' private practice office. All patients were African American, except 5 who self-reported as Latino; there were 35 female (71%) and 14 male (28%), aged 15 to 66 with a median age of 33 years; Table 1 outlines patient characteristics. Keloids



**Figure 1.** Typical clinical appearance of before keloid scar removal (A) and after following keloid treatment protocol (B).



**Figure 2.** African American male with keloid scar on the right outer ear lobule that occurred after piercing (A) and follow-up 6 months after keloid treatment protocol (B).

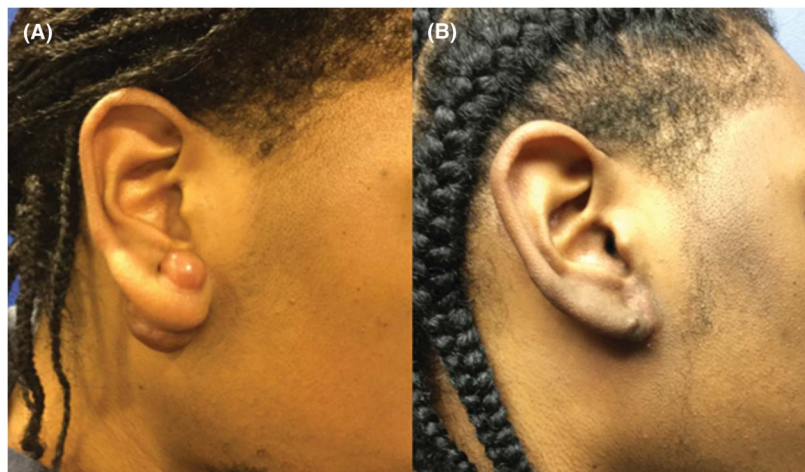
were localized to the ear, with 13 (27%) confined to the lobule and measured an average of  $2 \times 3$  cm. The treatment was well tolerated by all patients with no known or limited adverse reactions (e.g., hypertrophy/hyperpigmentation/wound dehiscence) reported after procedure and on follow-up. Patients were seen in-office for follow-up; however, in certain cases in which patients were unable to return for face-to-face follow-up, the authors had a nurse practitioner contact them by phone to confirm success of keloid treatment and requested photo documentation. Figures 1–3 illustrate before and after outcomes.

An important finding of this study is that a significant number of patient outcomes ( $n = 47$ , 95%) were considered successful and that there was 1 reported recurrence of keloids in this cohort, providing further support that the authors' unique combination of

therapies may provide patients with the permanent resolution of this particular type of keloid.

### Discussion

In general, keloids are considered benign lesions; however, because of their unknown etiology and often proliferative growth, they continue to be difficult to treat, causing patients often to suffer with pain and discomfort often causing significant psychological distress caused by their visibility. Aesthetic plastic surgeons have long wrestled with the treatment challenges posed by these lesions, and research in the field has determined that these salient growths respond better when treated with multiple approaches; however, currently, there is no consensus among the surgical community as to which method has the most optimal outcome. Previously reported studies have



**Figure 3.** African American male with  $7 \times 5$  cm left ear keloid who underwent extralesional excision followed by platelet-rich plasma and superficial radiation therapy with a cumulative dose of 18 Gy (A). Follow-up at 9 months demonstrates no evidence of recurrence (B).

yielded variable outcomes employing combination therapies such as surgical excision together with intralesional injections using antineoplastic agents, botulinum toxin, corticosteroid injections, and pressure splints.<sup>26,27</sup>

Limitations of this study include a small sample size and on average short follow-up of 2 years. Future prospective studies using this methodology should include a 2-group randomized design to allow for comparison of differences in outcomes. The preliminary findings of this retrospective analysis are encouraging, and the authors' protocol merits further investigation in the treatment and management of ear keloids.

### **Ethical Approval**

All procedures performed in studies involving human participants were in accordance with the ethical standards of the institutional and/or national research committee and with the 1964 Helsinki Declaration and its later amendments or comparable ethical standards.

### **References**

- Al-Attar A, Mess S, Thomassen JM, Kauffman CL, et al. Keloid pathogenesis and treatment. *Plast Reconstr Surg* 2006;117:286–300.
- Niessen FB, Spauwen PH, Schalkwijk J, Kon M. On the nature of hypertrophic scars and keloids: a review. *Plast Reconstr Surg* 1999;104:1435–58.
- Gauglitz GG, Korting HC, Pavicic T, Ruzicka T, et al. Hypertrophic scarring and keloids: pathomechanisms and current and emerging treatment strategies. *Mol Med* 2011;17:113–25.
- Jones ME, Hardy C, Ridgway J. Keloid management: a retrospective case review on a new approach using surgical excision, platelet-rich plasma, and in-office superficial photon x-ray radiation therapy. *Adv Skin Wound Care* 2016;29:303.
- Tripoli M, Cordova A, Melloni C, Zabbia G, et al. The use of triamcinolone combined with surgery in major ear keloid treatment: a personal two stages approach. *Eur J Plast Surg* 2015;38:205–10.
- Sasidharan A, David A, Gohil A, Gupta AK. Simple device to determine the pressure applied by pressure clips for the treatment of earlobe keloids. *Indian J Plast Surg* 2015;48:293–6.
- Kosir MA, Quinn CC, Wang W, Tromp G. Matrix glycosaminoglycans in the growth phase of fibroblasts: more of the story in wound healing. *J Surg Res* 2000;92:45–52.
- Sephel GC, Woodward SC. *Repair, Regeneration and Fibrosis*. Rubin E, editor. Baltimore, MD: Lippincott, Williams & Wilkins; 2001; pp. 84–117.
- Slemp AE, Kirschner RE. Keloids and scars: a review of keloids and scars, their pathogenesis, risk factors, and management. *Curr Opin Pediatr* 2006;18:396–402.
- Mehta S, Watson JT. Platelet rich concentrate: basic science and current clinical applications. *J Orthop Trauma* 2008;22:432–8.
- Bhanot S, Alex JC. Current applications of platelet gels in facial plastic surgery. *Facial Plast Surg* 2002;18:27–33.
- Lacci KM, Dardik A. Platelet-rich plasma: support for its use in wound healing. *Yale J Biol Med* 2010;83:1–9.
- Soffer E, Ouhayoun JP, Anagnostou F. Fibrin sealants and platelet preparations in bone and periodontal healing. *Oral Surg Oral Med Oral Pathol Oral Radiol Endod* 2003;95:521–8.
- Crovetti G, Martinelli G, Issi M, Barone M, et al. Platelet gel for healing cutaneous chronic wounds. *Transfus Apher Sci* 2004;30:145–51.
- Pietramaggiore G, Kaipainen A, Czczuga JM, Wagner CT, et al. Freeze-dried platelet-rich plasma shows beneficial healing properties in chronic wounds. *Wound Repair Regen* 2006;14:573–80.
- Harrison P, Cramer EM. Platelet alpha-granules. *Blood Rev* 1993;7:52–62.
- O'Shaughnessey KM, Panitch A, Woodell-May JE. Blood-derived anti-inflammatory protein solution blocks the effect of IL-1beta on human macrophages in vitro. *Inflamm Res* 2011;60:929–36.
- Nassiri M, Woolery-Lloyd H, Ramos S, Jacob SE, et al. Gene expression profiling reveals alteration of caspase 6 and 14 transcripts in normal skin of keloid-prone patients. *Arch Dermatol Res* 2009;301:183–8.
- Fabbro MD, Bortolin M, Taschieri S, Ceci C, et al. Antimicrobial properties of platelet-rich preparations. A systematic review of the current pre-clinical evidence. *Platelets* 2016;27:276–85.
- Bielecki TM, Gazdzik TS, Arendt J, Szczepanski T, et al. Antibacterial effect of autologous platelet gel enriched with growth factors and other active substances: an in vitro study. *J Bone Joint Surg Br* 2007;89:417–20.
- McGregor S, Minni J, Herold D. Superficial radiation therapy for the treatment of nonmelanoma skin cancers. *J Clin Aesthet Dermatol* 2015;8:12–4.
- Wolfe CM, Coggnetta AB. Radiation therapy (RT) for nonmelanoma skin cancer (NMSC), a cost comparison: clarifying misconceptions. *J Am Acad Dermatol* 2016;75:654–5.
- Song C, Wu HG, Chang H, Kim IH, et al. Adjuvant single-fraction radiotherapy is safe and effective for intractable keloids. *J Radiat Res* 2014;55:912–6.
- Yamawaki S, Naitoh M, Ishiko T, Muneuchi G, et al. Keloids can be forced into remission with surgical excision and radiation, followed by adjuvant therapy. *Ann Plast Surg* 2011;67:402–6.
- Yamawaki S, Naitoh M, Yoshikawa K, Ishiko T, et al. Kyoto scar scale for assessment of keloids following surgery and irradiation. *Sosyo* 2011;2:112–7.
- Walliczek U, Engel S, Weiss C, Aderhold C, et al. Clinical outcome and quality of life after a multimodal therapy approach to ear keloids. *JAMA Facial Plast Surg* 2015;17:333–9.
- Wilson AM. Eradication of keloids: surgical excision followed by a single injection of intralesional 5-fluorouracil and botulinum toxin. *Can J Plast Surg* 2013;21:87–91.

---

Address correspondence and reprint requests to: Christine A. Ganzer, PMHNP, PhD, Hunter-Bellevue School of Nursing, Hunter College, New York, NY 10010, or e-mail: cganzer@hunter.cuny.edu